





<https://vizle.offnote.co>

Contact us: vizle@offnote.co

This document was generated automatically by **Vizle**

Your **Personal Video Reader Assistant**

Learn from Videos **Faster** and **Smarter**

VIZLE PRO / BIZ

PDF, PPT ~~Watermarks~~

- Convert *entire* videos
- *Customize* to retain all essential content
- Include Spoken *Transcripts*
- Customer support

Visit <https://vizle.offnote.co/pricing> to learn more

VIZLE FREE PLAN

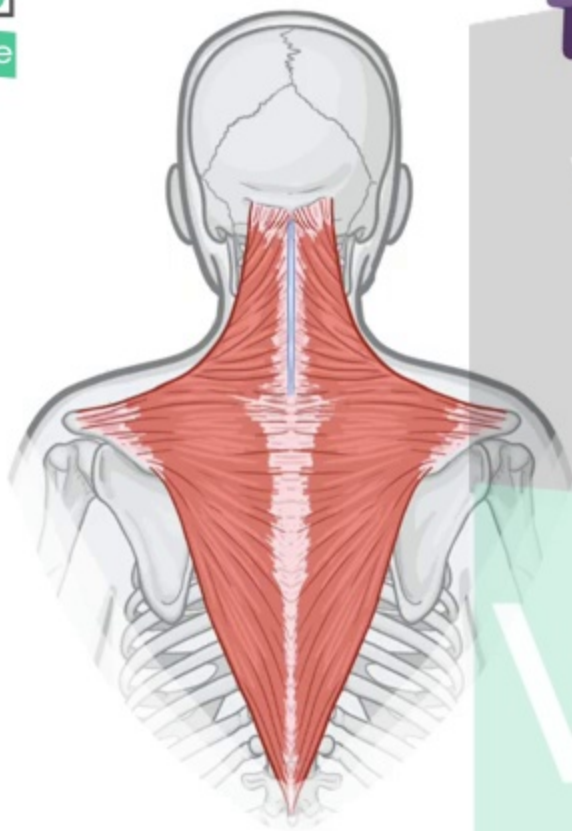
PDF only ~~Watermarks~~

- Convert videos *partially*
- Slides may be *skipped**
- Usage restrictions
- No Customer support

Visit <https://vizle.offnote.co> to try free

Login to Vizle to unlock more slides*

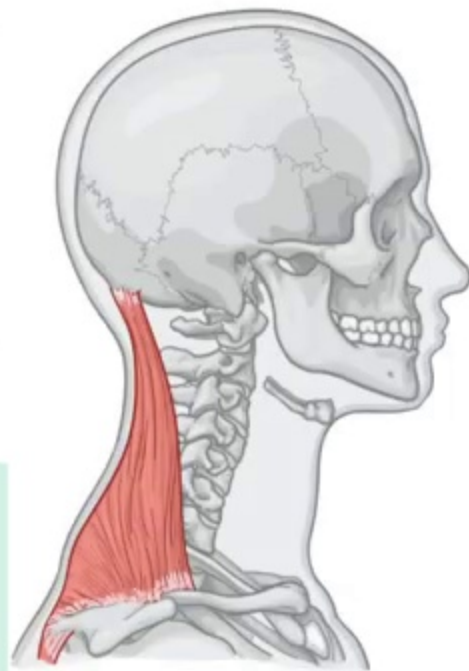
TRAPEZIUS



V



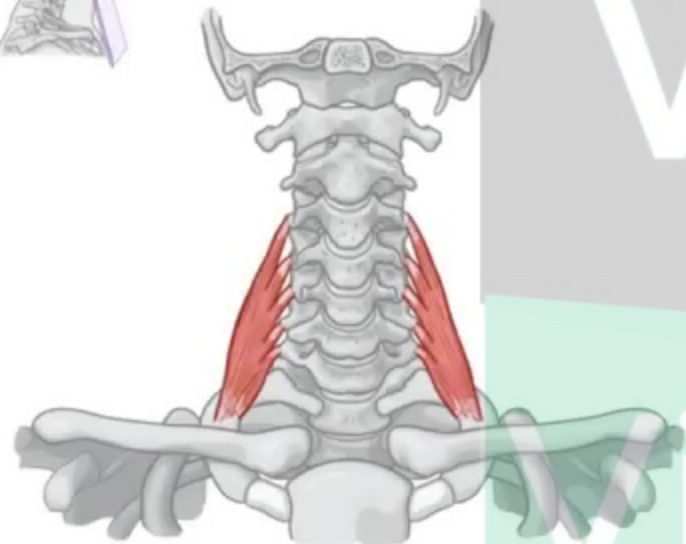
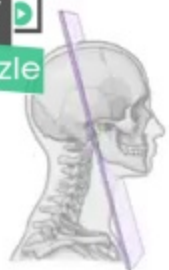Vizle



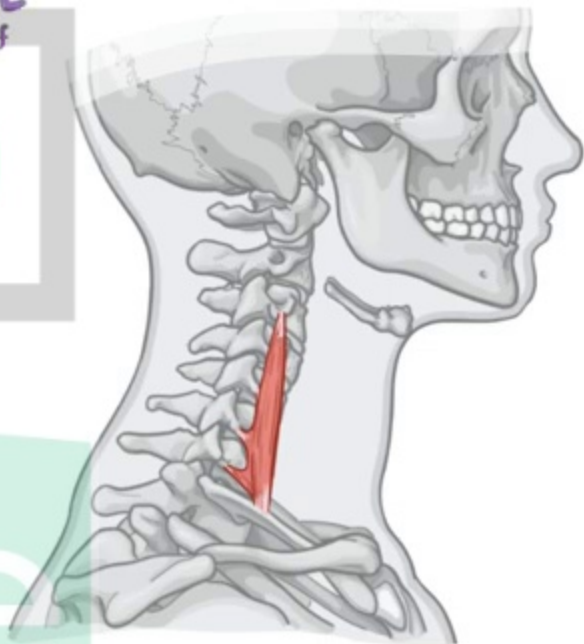
FLOOR of POSTERIOR TRIANGLE

* MIDDLE SCALENE

↳ LARGEST & LONGEST of
3 SCALENE MUSC



ANTERIOR



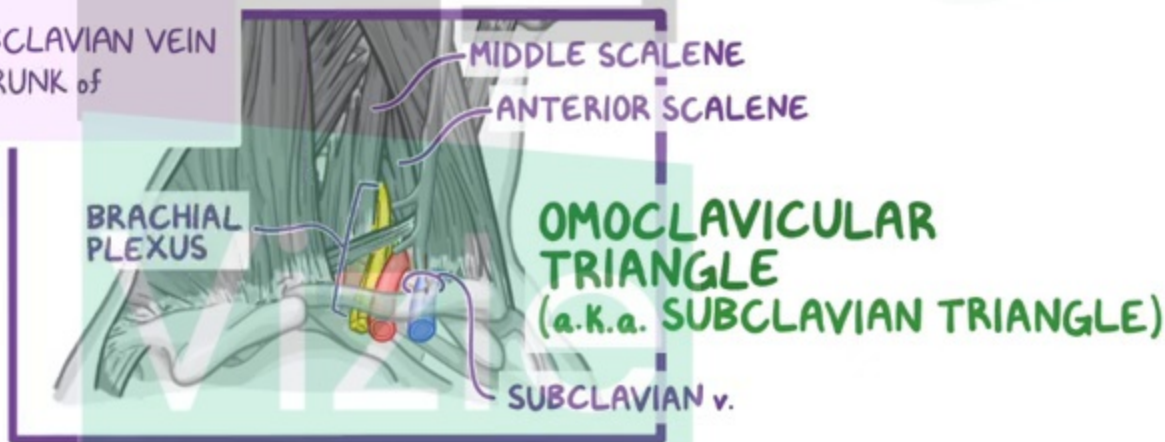
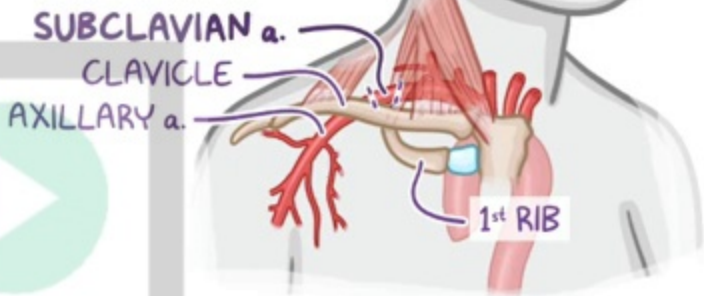
vizle

SUBCLAVIAN ARTERY

- ARCHES MEDIAL to CLAVICLE
- ~ PASSES BETWEEN ANTERIOR & MIDDLE SCALENE

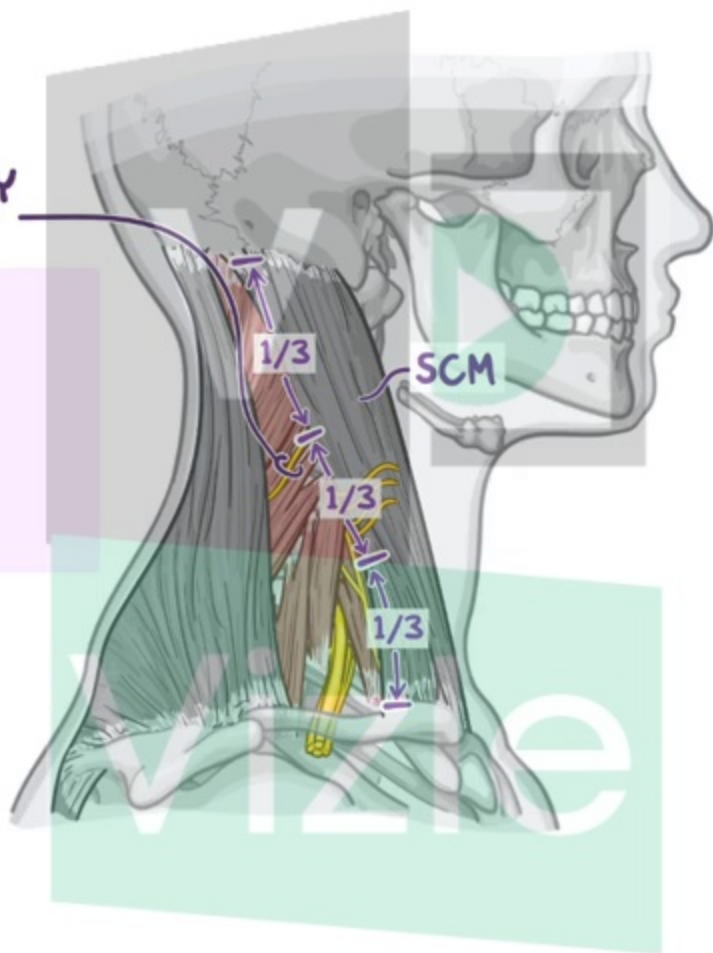
3rd PART of SUBCLAVIAN a.

- * LONGEST & MOST SUPERFICIAL PART
- ~ DEEP in INFERIOR PART of OMOCLAVICULAR TRIANGLE
- ~ in CONTACT with 1st RIB
- ~ POSTEROSUPERIOR to SUBCLAVIAN VEIN
- ~ ANTERIOR to INFERIOR TRUNK of BRACHIAL PLEXUS



SPINAL ACCESSORY NERVE (CN XI)

* INNERVATES SCM





<https://vizle.offnote.co>

Contact us: vizle@offnote.co

This document was generated automatically by **Vizle**

Your **Personal Video Reader Assistant**

Learn from Videos **Faster** and **Smarter**

VIZLE PRO / BIZ

PDF, PPT ~~Watermarks~~

- Convert *entire* videos
- *Customize* to retain all essential content
- Include Spoken *Transcripts*
- Customer support

Visit <https://vizle.offnote.co/pricing> to learn more

VIZLE FREE PLAN

PDF only ~~Watermarks~~

- Convert videos *partially*
- Slides may be *skipped**
- Usage restrictions
- No Customer support

Visit <https://vizle.offnote.co> to try free

Login to Vizle to unlock more slides*