

V  
Vizle

Vizle



<https://vizle.offnote.co>

Contact us: [vizle@offnote.co](mailto:vizle@offnote.co)

This document was generated automatically by **Vizle**

Your **Personal Video Reader Assistant**

Learn from Videos **Faster** and **Smarter**

### VIZLE PRO / BIZ

- Convert *entire* videos <sup>PDF, PPT</sup>
- *Customize* to retain all essential content
- Include Spoken *Transcripts*
- Customer support

Visit <https://vizle.offnote.co/pricing> to learn more

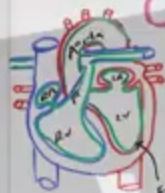
### VIZLE FREE PLAN

- Convert videos *partially* <sup>PDF only</sup>
- Slides may be *skipped*\*
- Usage restrictions
- No Customer support

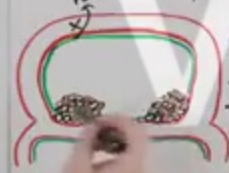Visit <https://vizle.offnote.co> to try free

**Login to Vizle** to unlock more slides\*

# CAUSES

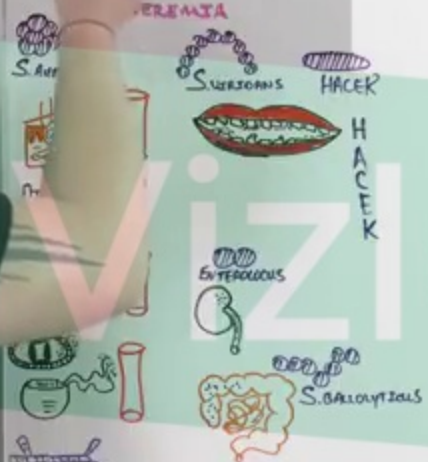


ACUTE J.E.  
 → SEPTIC  
 → VIRULENT PATHOGEN  
 → S. AUREUS  
 SUBACUTE J.E.  
 → NOT SUPER SECK  
 → ↓ virulent pathogens  
 → S. VIRIDANS




ABNORMAL VALVES  
 → RHD (YYYY)  
 → Hx of J.E.  
 → Biopso AoV  
 → M.V.P.  
 → C.H.D.  
 → USG's

## EMBRYOLOGY



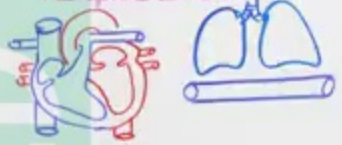
# CLINICAL FEATURES AND PHYS



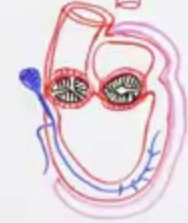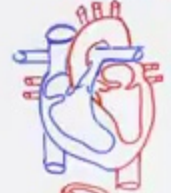
↑ CYTOKINES



↑ SEPTIC EMBOLI

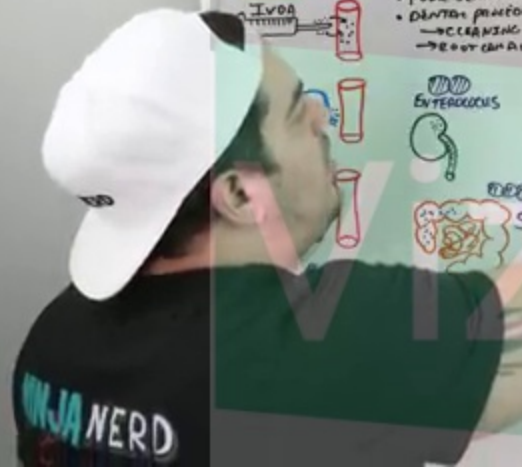


↑ VALVE AND DES



↑ I





**VIZIE**

# CAUSES

Acute I.E. → SEPTIC → INVALENT PATHOGEN → S. AUREUS

Subacute I.E. → NOT SUPER SECK → ↓ Virulent pathogens → S. VIRIDANS

Abnormal Valves → RHD (Y Y Y Y) Hx of I.E. Prolapsed AVV

1. V. P. H. D. ASD's

MITRAL VALVE

Acute I.E. → GAMMA → HACKER

Haemophilius

Subacute

Staphylococcus

# CLINICAL FEATURES AND PHYSICAL EXAM

↑ CYTOKINES

↑ VALVE AND PERIVALVULAR DESTRUCTION

↑ SEPTIC EMBOLI

↑ IMMUNE COMPLEXES

# DIAGNOSIS

ECHOCARDIOGRAPHY

TESTS FOR

MAJOR CRITERIA ← MODIFIED DUKAN

The diagrams illustrate the progression of infective endocarditis. They show cross-sections of heart valves with vegetations (masses of bacteria and fibrin) attached. Some diagrams show abscesses in the myocardium or perivalvular abscesses. Other diagrams show valve destruction and regurgitation. There are also diagrams of emboli (clots) in the bloodstream and immune complexes.

**VIZIE**

# CAUSES

**Acute I.E.**  
 → SEPTIC  
 → INVALENT PATHOGEN  
 → SAUBERS

**Subacute I.E.**  
 → NOT SUPER COCK  
 → ↓ Virulent pathogens  
 → S. VIRIDANS

**Abnormal Valves**  
 → RHD (Y Y Y Y)  
 → Hx of I.E.  
 → Bicuspid AOV  
 → M.V.  
 → C.H.  
 → PAH

**Bacteremia**  
 → Acute I.E.  
 → SUGAR  
 → SURGERY  
 → ANTIBIOTICS  
 → IVDA  
 → CVC  
 → P.V.  
 → AIC

# CLINICAL FEATURES AND PHYSICAL EXAM

**↑ CYTOKINES**  
 → LA  
 → IL-1, IL-2, IL-6, TNF- $\alpha$

**↑ VALVE AND PERIVALVULAR DESTRUCTION**  
 → PROTEASES  
 → FIBROSIS  
 → VALVE DESTRUCTION + PERIVALVULAR DESTRUCTION

**↑ SEPTIC EMBOLI**  
 → RAM  
 → FEVER  
 → LEUKAEMIA

**↑ IMMUNE COMPLEXES**

**1) NBT**  
**2) Microbial vegetation**  
**3) Immune complex**  
 → IL-1, IL-2, IL-6, TNF- $\alpha$

**Septic emboli**  
**Immune complexes**

# DIAGNOSIS

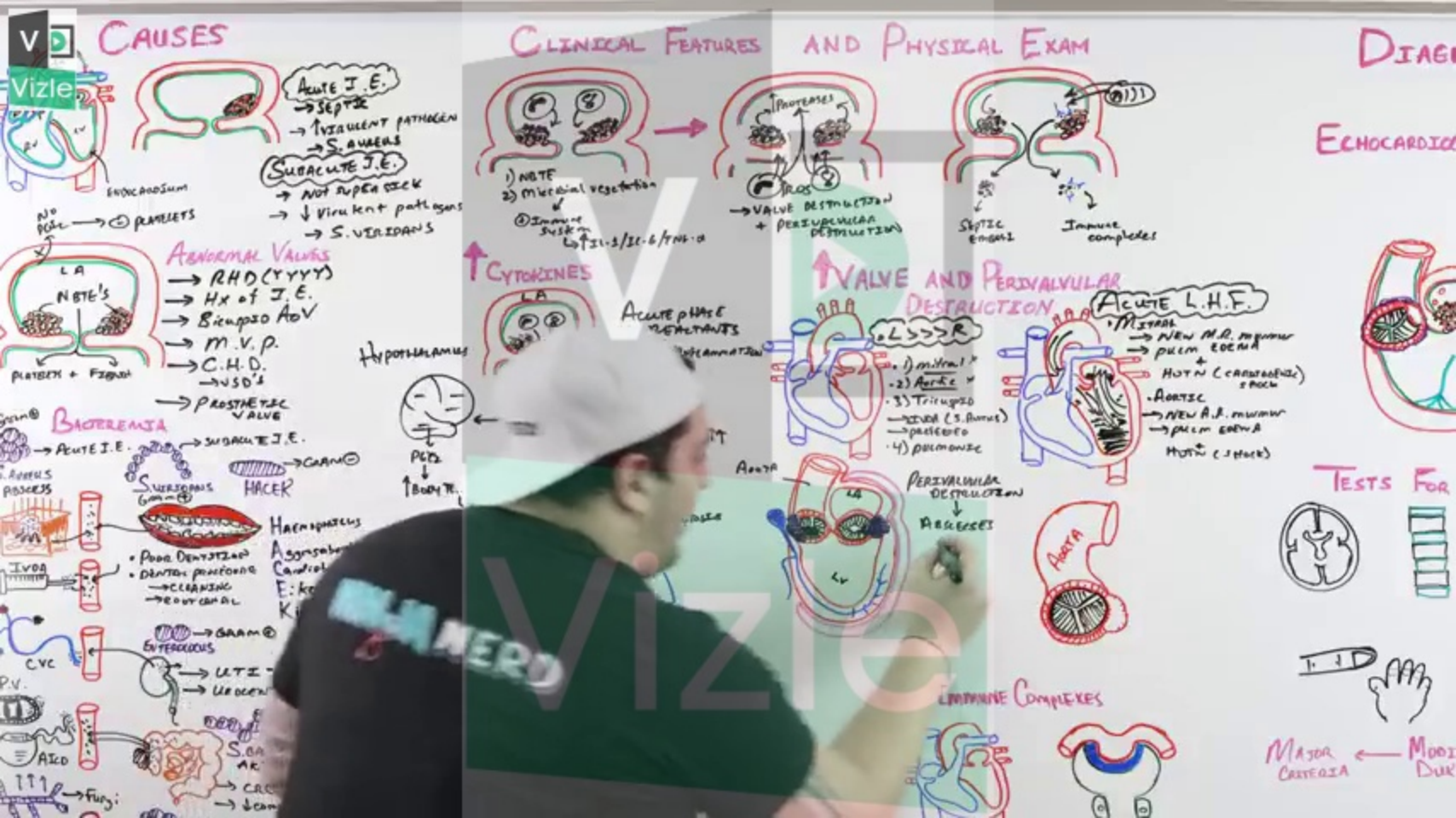
## ECHOCARDIOGRAPHY

**TESTS FOR**

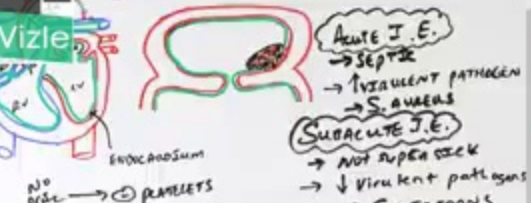
**MAJOR CRITERIA** ← **MODIFIED DUK**

**MINIJA NERD**

The diagrams illustrate the progression of infective endocarditis. One diagram shows a heart with vegetations on the mitral valve and aortic valve. Another shows a heart with a large vegetation on the mitral valve and aortic valve. A third diagram shows a heart with a large vegetation on the mitral valve and aortic valve, and a fourth diagram shows a heart with a large vegetation on the mitral valve and aortic valve. The diagrams also show the heart with a large vegetation on the mitral valve and aortic valve, and a fifth diagram shows a heart with a large vegetation on the mitral valve and aortic valve.



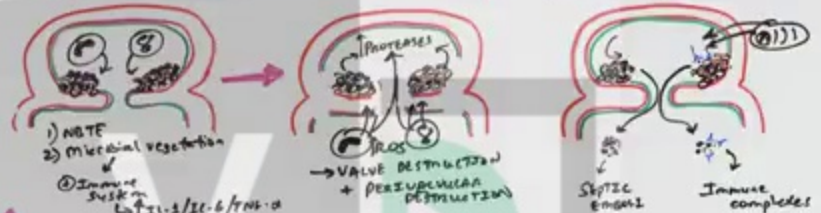
# CAUSES



**Abnormal Valves**  
→ RHD (Y Y Y Y)  
→ Hx of I.E.  
→ Stenosis A/V  
→ M.V.P.  
→ C.H.D.  
→ USD's  
→ PROSTHETIC VALVE

**BACTEREMIA**  
→ Acute I.E.  
→ Subacute I.E.  
→ HAEC  
→ HAEMOPHILUS  
→ Asymptomatic Carotid E: ko K  
→ Enterococcus  
→ UTI  
→ Urogen  
→ S. GA AR  
→ CRC  
→ ↓ cam  
→ Fungi

# CLINICAL FEATURES AND PHYSICAL EXAM

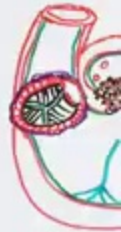

**↑ CYTOKINES**  
Acute phase reactants  
Hypothalamus  
PGE2  
↑ Body T

**↑ VALVE AND PERIVALVULAR DESTRUCTION**  
Aortic: 1) mitral, 2) Aortic, 3) Tricuspid, 4) Pulmonic  
PERIVALVULAR DESTRUCTION → ABSCESS  
Acute L.H.F. Mitral: New A.R. murmur, pulm edema, Hx of CAD/stroke, Aortic: New A.S. murmur, pulm edema, Hx of stroke

# DIAGNOSIS

## ECHOCARDIOGRAM

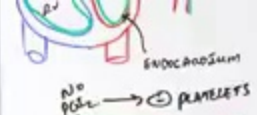

## TESTS FOR



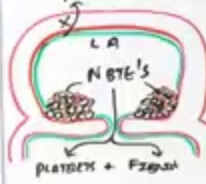
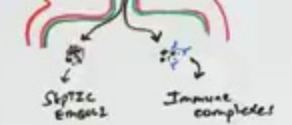
## EMPIRIC COMPLEXES

Major Criteria ← Minor Criteria



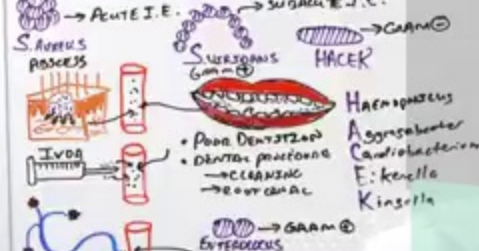**SUBACUTE I.E.**  
 → NOT SUPER INFECTION  
 → VIRULENT PATHOGENS  
 → S. VIRIDANS

- 1) NBTE
  - 2) Microbial vegetation
- Immune susk  
 LA 21-3/21-6/TMS-0

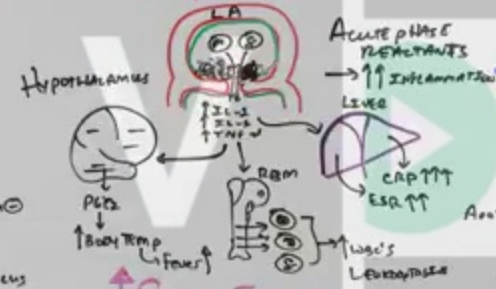

**ABNORMAL VALVES**  
 → RHD (YYYY)  
 → Hx of I.E.  
 → Bicuspid AOV  
 → M.V.P.  
 → C.H.D.  
 → USD's  
 → PROSTHETIC VALVE

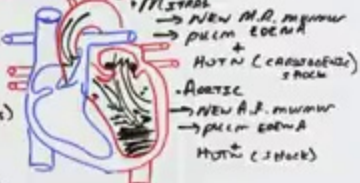
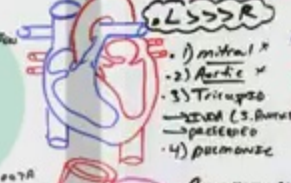
**BACTEREMIA**



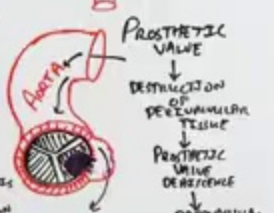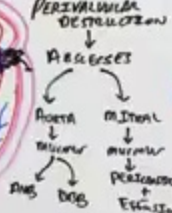
**↑ CYTOKINES**



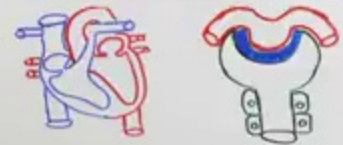
**↑ VALVE AND PERIVALVULAR DESTRUCTION**



**↑ Sepsis Emboli**



**↑ IMMUNE COMPLEXES**



MAJOR CAUSE

WINJANERD





<https://vizle.offnote.co>

Contact us: [vizle@offnote.co](mailto:vizle@offnote.co)

This document was generated automatically by **Vizle**

Your **Personal Video Reader Assistant**

Learn from Videos **Faster** and **Smarter**

### VIZLE PRO / BIZ

- Convert *entire* videos <sup>PDF, PPT</sup>
- *Customize* to retain all essential content
- Include Spoken *Transcripts*
- Customer support

Visit <https://vizle.offnote.co/pricing> to learn more

### VIZLE FREE PLAN

- Convert videos *partially* <sup>PDF only</sup>
- Slides may be *skipped*\*
- Usage restrictions
- No Customer support

Visit <https://vizle.offnote.co> to try free

**Login to Vizle** to unlock more slides\*