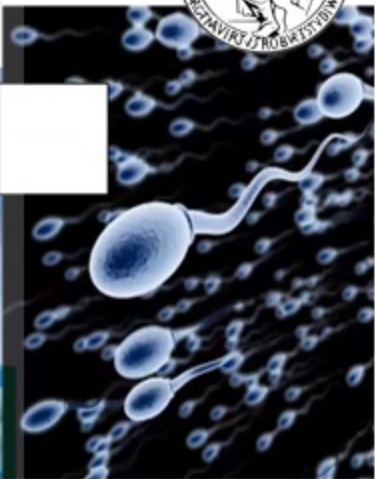
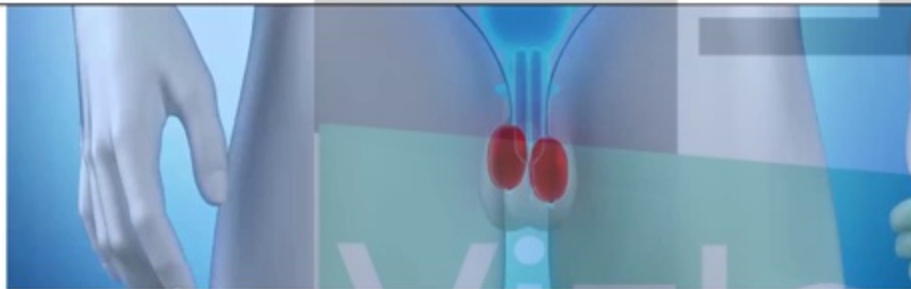




Reproductor masculino



Unidad Académica II
Departamento de Ciencias Fisiológicas
Facultad de Medicina. UBA

Dr. Juan Manuel Gamez



<https://vizle.offnote.co>

Contact us: vizle@offnote.co

This document was generated automatically by **Vizle**

Your **Personal Video Reader Assistant**

Learn from Videos **Faster** and **Smarter**

VIZLE PRO / BIZ

- Convert *entire* videos ^{PDF, PPT}
- *Customize* to retain all essential content
- Include Spoken *Transcripts*
- Customer support

Visit <https://vizle.offnote.co/pricing> to learn more

VIZLE FREE PLAN

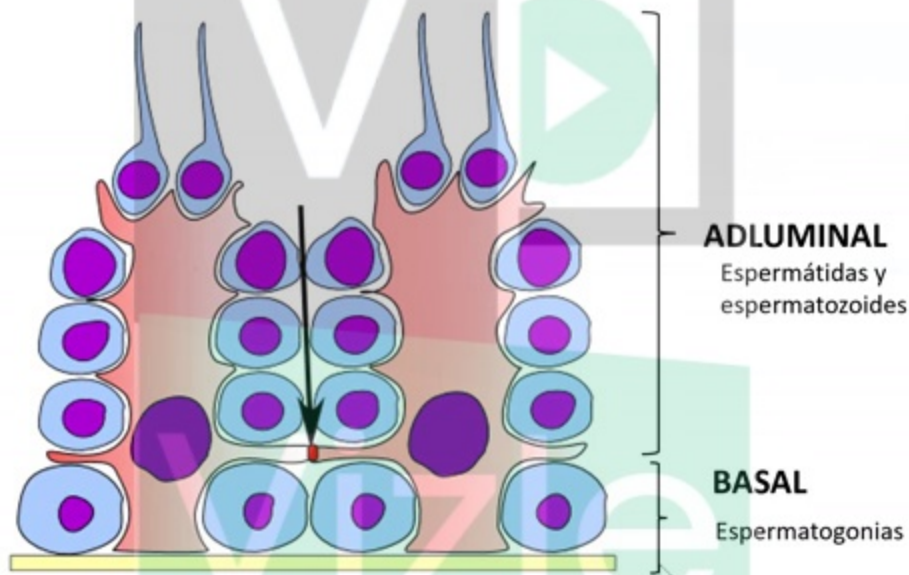
- Convert videos *partially* ^{PDF only}
- Slides may be *skipped**
- Usage restrictions
- No Customer support

Visit <https://vizle.offnote.co> to try free

Login to Vizle to unlock more slides*

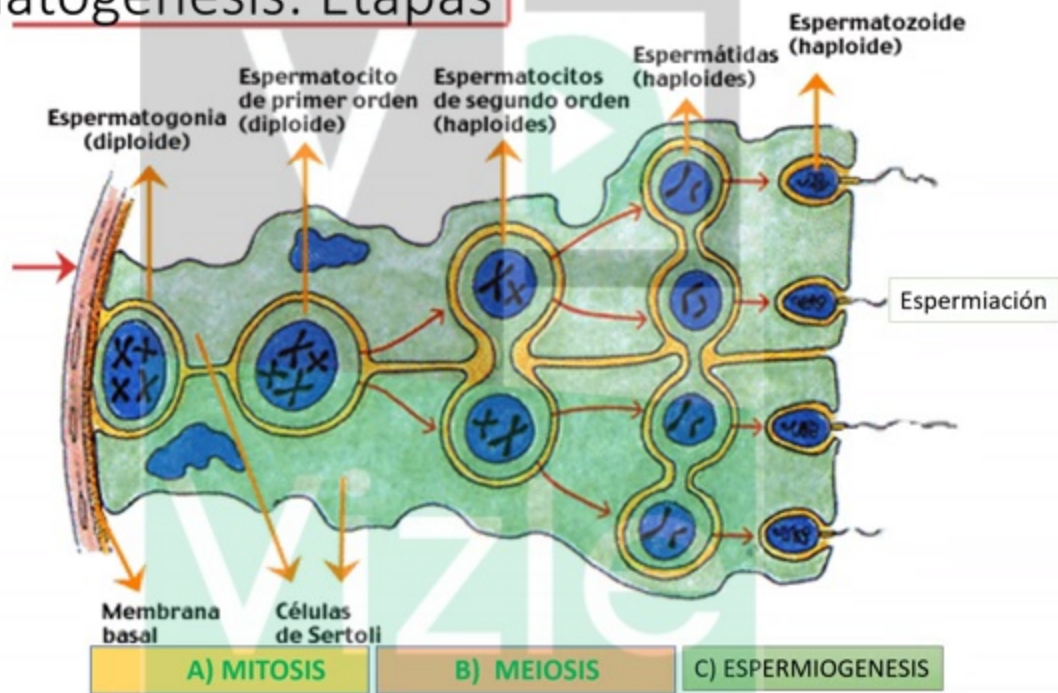


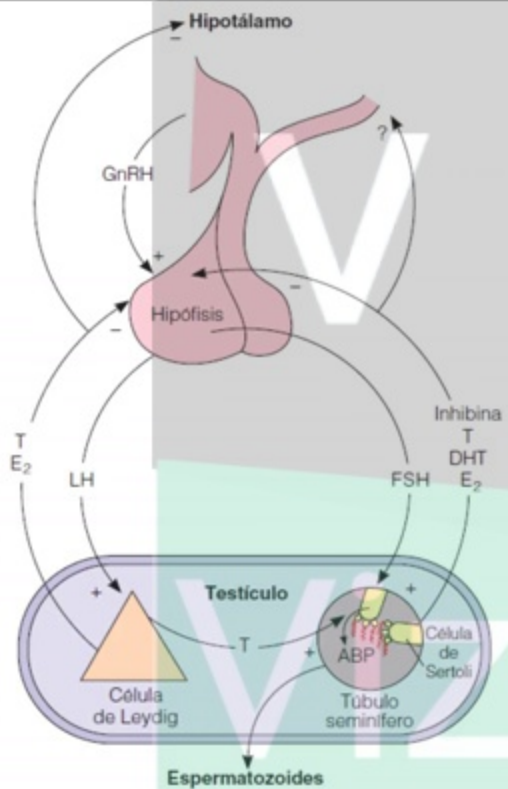
Barrera Hemato-testicular (BHT)





Espermatogénesis: Etapas





Eje Hipotálamo hipófiso testicular



Evaluación del eje gonadal masculino

- Determinaciones basales:

- Gonadotrofinas:

- Aumento: insuf. Testicular 1°.
- LH normal y FSH aumentada: Alt. Sertoli

- Testosterona:

- Disminución: hipogonadismo 1° ó 2°.

- Pruebas de estímulo:

- Test de GnRH:

- 100 ug iv en bolo.
- Muestras: basal, 30, 60 y 90 min.
- Rpta normal:
 - LH aumenta hasta 35 mUI/ml.
 - FSH aumenta hasta 25 mUI/ml.



<https://vizle.offnote.co>

Contact us: vizle@offnote.co

This document was generated automatically by **Vizle**

Your **Personal Video Reader Assistant**

Learn from Videos **Faster** and **Smarter**

VIZLE PRO / BIZ

- Convert *entire* videos ^{PDF, PPT}
- *Customize* to retain all essential content
- Include Spoken *Transcripts*
- Customer support

Visit <https://vizle.offnote.co/pricing> to learn more

VIZLE FREE PLAN

- Convert videos *partially* ^{PDF only}
- Slides may be *skipped**
- Usage restrictions
- No Customer support

Visit <https://vizle.offnote.co> to try free

Login to Vizle to unlock more slides*