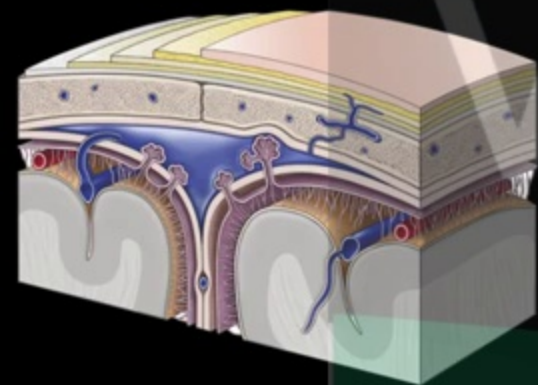




Meninges and Dural venous sinuses



Vizle



<https://vizle.offnote.co>

Contact us: vizle@offnote.co

This document was generated automatically by **Vizle**

Your **Personal Video Reader Assistant**

Learn from Videos **Faster** and **Smarter**

VIZLE PRO / BIZ

PDF, PPT Watermarks

- Convert *entire* videos
- *Customize* to retain all essential content
- Include Spoken *Transcripts*
- Customer support

Visit <https://vizle.offnote.co/pricing> to learn more

VIZLE FREE PLAN

PDF only Watermarks

- Convert videos *partially*
- Slides may be *skipped**
- Usage restrictions
- No Customer support

Visit <https://vizle.offnote.co> to try free

Login to Vizle to unlock more slides*

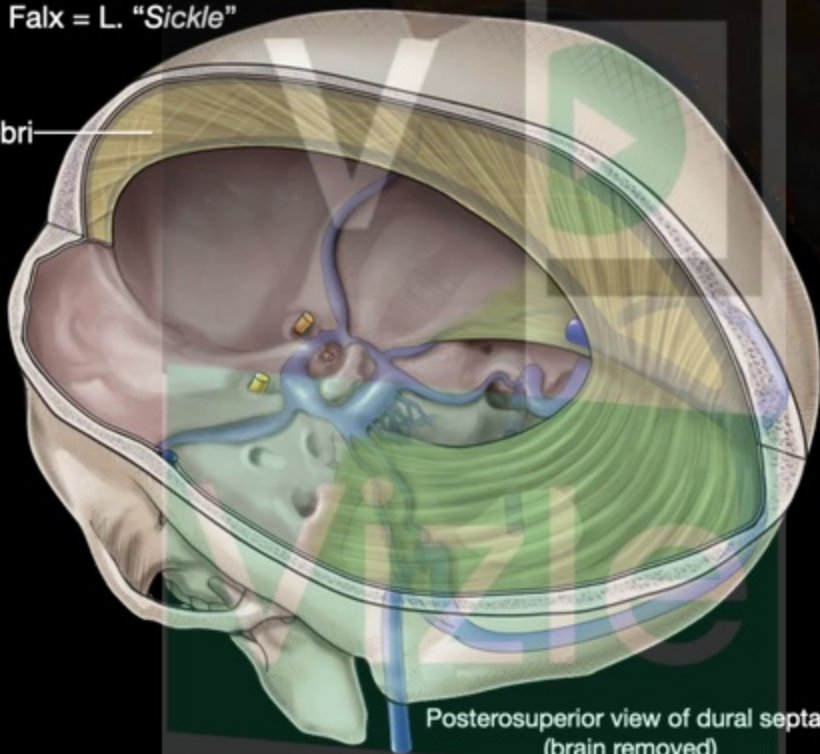
V a mater

Vizle dural septae

Falx cerebri

Falx = L. "Sickle"

Falx cerebri



Posterosuperior view of dural septae
(brain removed)

v a mater

Dural venous sinuses (DVS)

Venous channels located between the periosteal and meningeal layers of dura mater

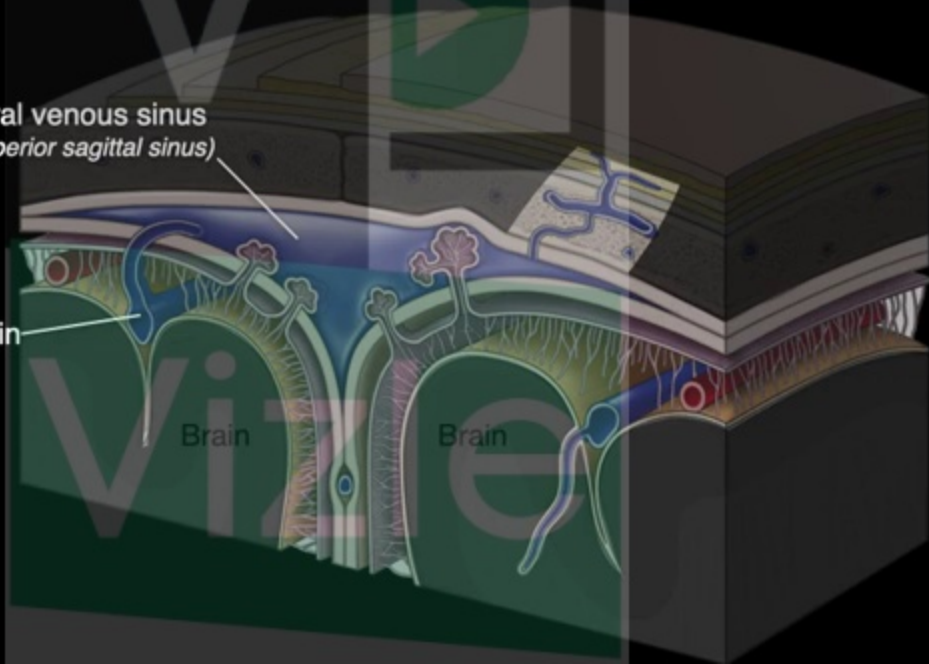
Receive blood from cerebral, diploic and emissary veins

Dural venous sinus
(Superior sagittal sinus)

Cerebral vein

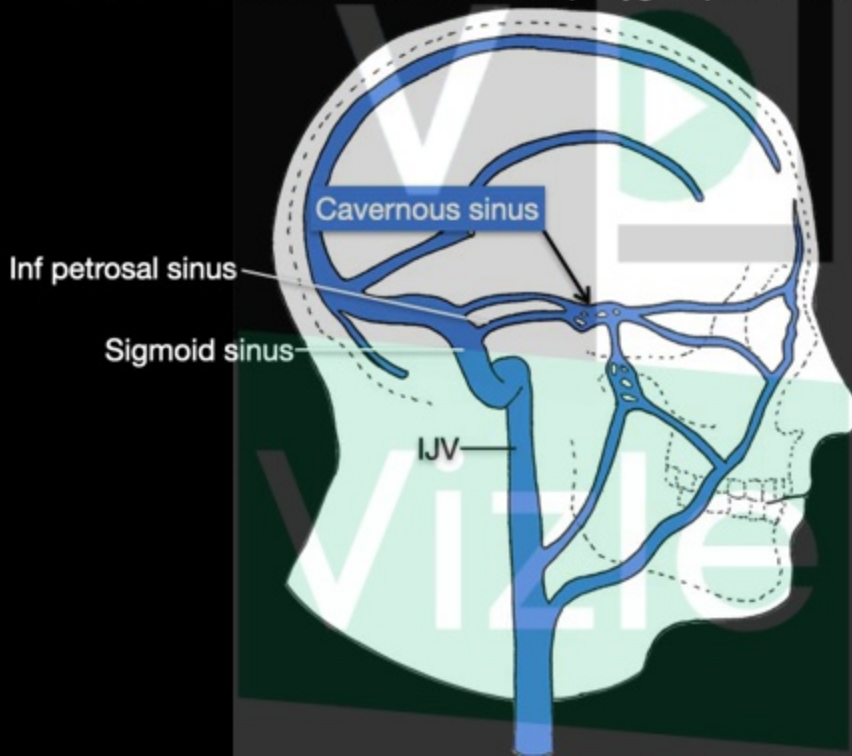
Brain

Brain



Cavernous sinus

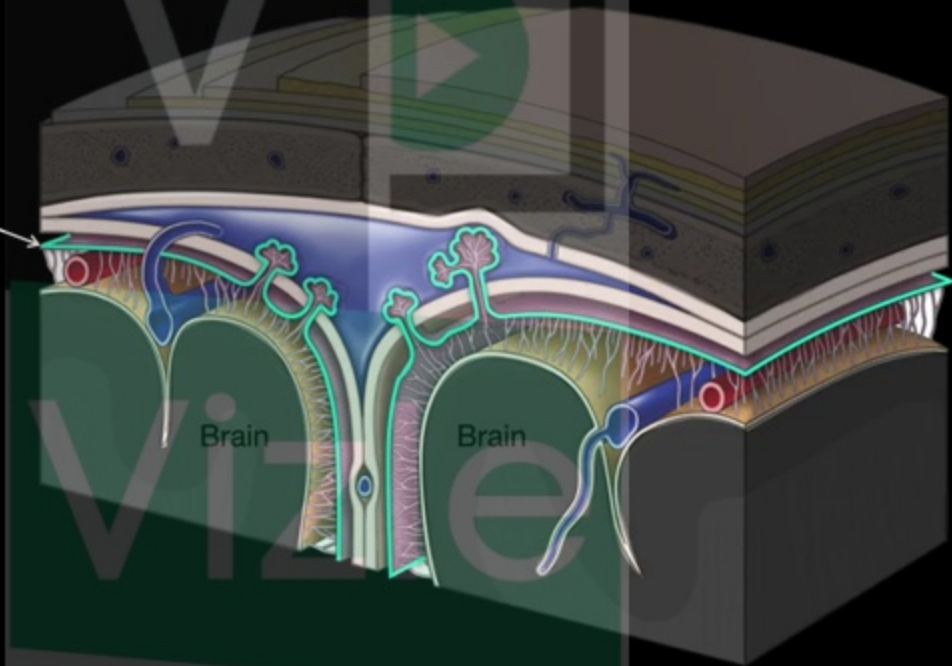
Communicates with the facial vein and pterygoid plexus of veins



Arachnoid mater

Vizie "epider-like" L. "mother"

Arachnoid mater





<https://vizle.offnote.co>

Contact us: vizle@offnote.co

This document was generated automatically by **Vizle**

Your **Personal Video Reader Assistant**

Learn from Videos **Faster** and **Smarter**

VIZLE PRO / BIZ

PDF, PPT ~~Watermarks~~

- Convert *entire* videos
- *Customize* to retain all essential content
- Include Spoken *Transcripts*
- Customer support

Visit <https://vizle.offnote.co/pricing> to learn more

VIZLE FREE PLAN

PDF only ~~Watermarks~~

- Convert videos *partially*
- Slides may be *skipped**
- Usage restrictions
- No Customer support

Visit <https://vizle.offnote.co> to try free

Login to Vizle to unlock more slides*