





<https://vizle.offnote.co>

Contact us: vizle@offnote.co

This document was generated automatically by **Vizle**

Your **Personal Video Reader Assistant**

Learn from Videos **Faster** and **Smarter**

VIZLE PRO / BIZ

- Convert *entire* videos ^{PDF, PPT}
- *Customize* to retain all essential content
- Include Spoken *Transcripts*
- Customer support

Visit <https://vizle.offnote.co/pricing> to learn more

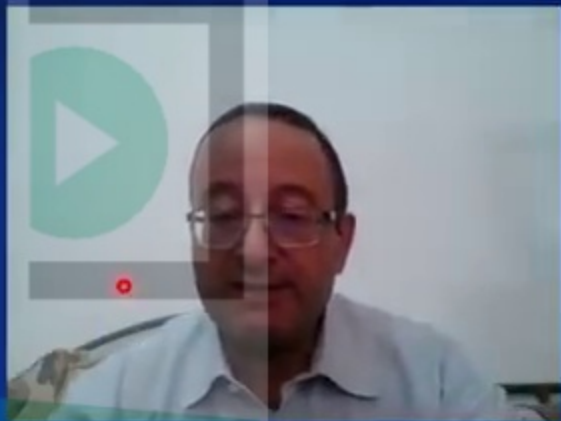
VIZLE FREE PLAN

- Convert videos *partially* ^{PDF only}
- Slides may be *skipped**
- Usage restrictions
- No Customer support

Visit <https://vizle.offnote.co> to try free

Login to Vizle to unlock more slides*

Occipitofrontalis

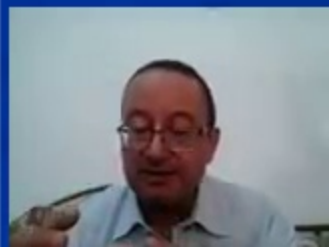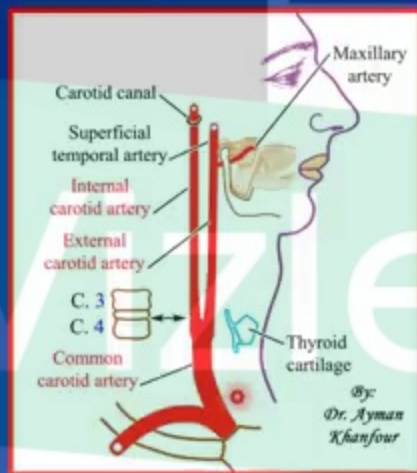


Vizle

Blood Supply

Branches from
External
Carotid Artery

Branches from
Internal
Carotid Artery



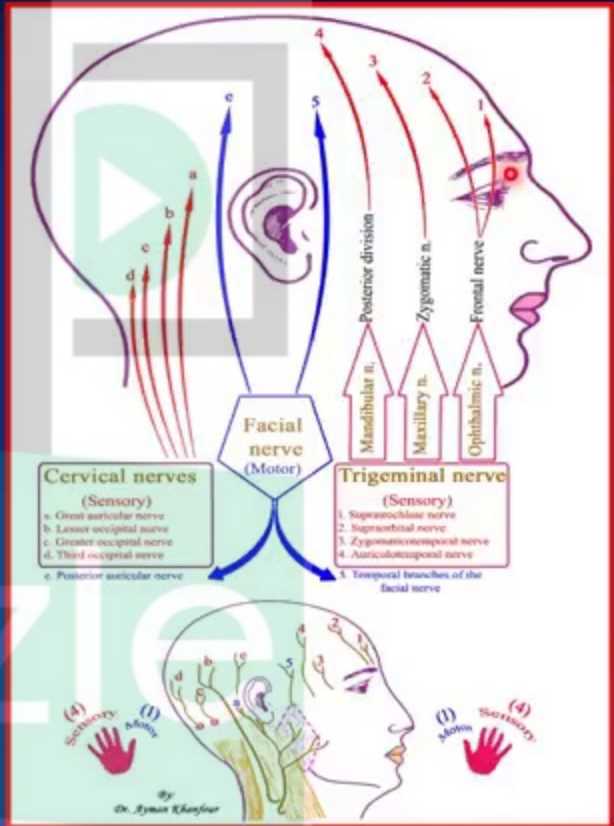


Nerves "in front of" the auricle: ----- (5)

A. Sensory supply (4)

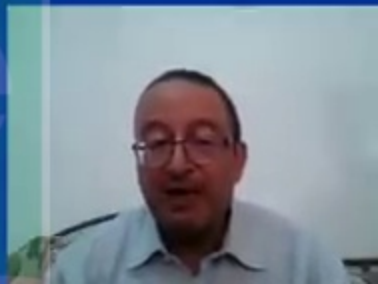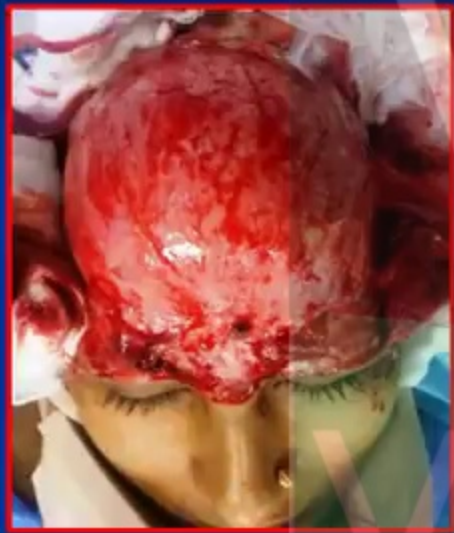- They all arise from the *trigeminal nerve*.

1. Supratrochlear n.
2. Supraorbital n.
3. Zygomatico-temporal n.



Applied Anatomy

1. Scalping (avulsion of the scalp - نزع فروة الرأس)





<https://vizle.offnote.co>

Contact us: vizle@offnote.co

This document was generated automatically by **Vizle**

Your **Personal Video Reader Assistant**

Learn from Videos **Faster** and **Smarter**

VIZLE PRO / BIZ

- Convert *entire* videos ^{PDF, PPT}
- *Customize* to retain all essential content
- Include Spoken *Transcripts*
- Customer support

Visit <https://vizle.offnote.co/pricing> to learn more

VIZLE FREE PLAN

- Convert videos *partially* ^{PDF only}
- Slides may be *skipped**
- Usage restrictions
- No Customer support

Visit <https://vizle.offnote.co> to try free

Login to Vizle to unlock more slides*