



SOCIEDAD CHILENA DE ULTRASONOGRAFIA
EN MEDICINA Y BIOLOGIA

vizie

This PDF is generated automatically by **Vizle**.
Slides created *only for a few minutes* of your Video.



For the full PDF, please **Login to Vizle**.

<https://vizle.offnote.co> (Login via Google, top-right)

Stay connected with us:

Join us on **Facebook, Discord, Quora, Telegram**.



Características clínicas y pronóstico del Tumor Seroso Borderline

- Edad 39a y presenta síntomas solo el 30%
- La mayoría de los casos están confinados al ovario
- CA 125 promedio de 31,3 (2-939,2)
- 13% tienen enfermedad extra-ovárica (implantes)
- La sobrevida sin implantes es de 99% y 98% a los 5 y 10 a.
- Sobrevida con implantes de 95% y 90% a los 5 y 10 a.

Variable	
Age at diagnosis (year)	
Nulliparous	23 (35.9)
Postmenopausal	12 (18.8)
Presence of symptoms*	19 (29.7)
Main symptom	
Abdominal distension	3 (4.7)
Abdominal pain	8 (12.5)
Abnormal bleeding	3 (4.7)
Change in bowel function	0 (0.0)
Other	5 (7.8)
No symptoms	45 (70.3)
CA 125 at diagnosis (IU/mL)†	31.3 (2-939.2)
Surgical treatment‡	
Conservative	36/63 (57.1)
Unilateral cystectomy	13/63 (20.6)
Bilateral cystectomy	3/63 (4.8)
Unilateral oophorectomy	16/63 (25.4)
Unilateral oophorectomy and contralateral cystectomy	4/63 (6.3)
Non-conservative	27/63 (42.9)
Biopsy	0/63 (0.0)
FIGO stage§	
I	51/62 (82.3)
II	3/62 (4.8)
III	8/62 (12.9)
IV	0/62 (0.0)



Papila



Variable	Benign (n = 131)	Borderline (n = 42)	Malignant		P*
			Primary invasive and metastasis (n = 31)	All (n = 71)	
Number of papillations					< 0.001
1	84 (64)	16 (38)	7 (23)	23 (32)	
2	14 (11)	3 (2)	4 (13)	5 (7)	
3	15 (11)	5 (12)	3 (10)	8 (11)	
> 3	18 (14)	20 (48)	17 (55)	37 (51)	
Height of largest papillation (mm)					< 0.001
Mean ± SD	10 ± 7	16 ± 10	24 ± 14	19 ± 12	
Median (range)	7 (3-44)	14 (7-60)	20 (4-54)	16 (4-60)	
Flow inside at least one papillation	36 (27)	34 (81)	29 (94)	63 (86)	< 0.001
Irregular contour in at least one papillation	81 (62)	39 (93)	26 (84)	65 (89)	< 0.001
Papillary dissemination					< 0.001
< 25%	96 (73)	6 (14)	10 (32)	16 (22)	
25-50%	27 (21)	21 (50)	9 (29)	30 (41)	
> 50%	8 (6)	15 (36)	12 (39)	27 (37)	
Papillary angle					0.21
< 90°	28 (21)	8 (19)	1 (3)	9 (12)	
≥ 90°	12 (9)	1 (2)	4 (13)	5 (7)	
Both < 90° and ≥ 90° in same cyst	91 (69)	33 (79)	26 (84)	59 (81)	
Acoustic shadows behind at least one papillation	37 (28)	1 (2)	3 (10)	4 (5)	< 0.001
Anechoic spaces inside at least one papillation	31 (24)	26 (62)	18 (58)	44 (60)	< 0.001
At least one hyperechoic papillation	45 (34)	5 (12)	9 (29)	14 (19)	0.02
Hyperechoic focus with acoustic shadows in papillations or in cyst wall	12 (9)	0 (0)	0 (0)	0 (0)	0.005
Confluent papillations	9 (7)	22 (52)	14 (45)	36 (49)	< 0.001

Mayor a 3 papilas

Altura papila mayor

Flujo presente

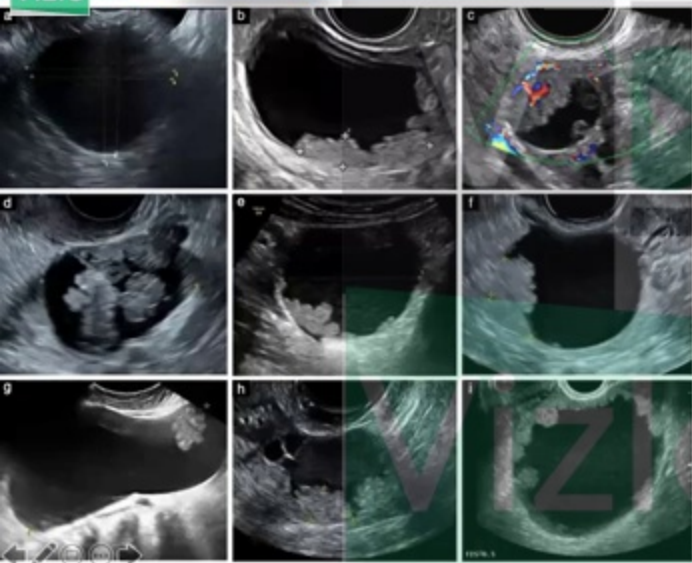
Irregularidad

Diseminación (25-50%, >50%)

Ambos ángulo < 90° ≥ 90°

Espacios anecoicos

Confluencia de papilas

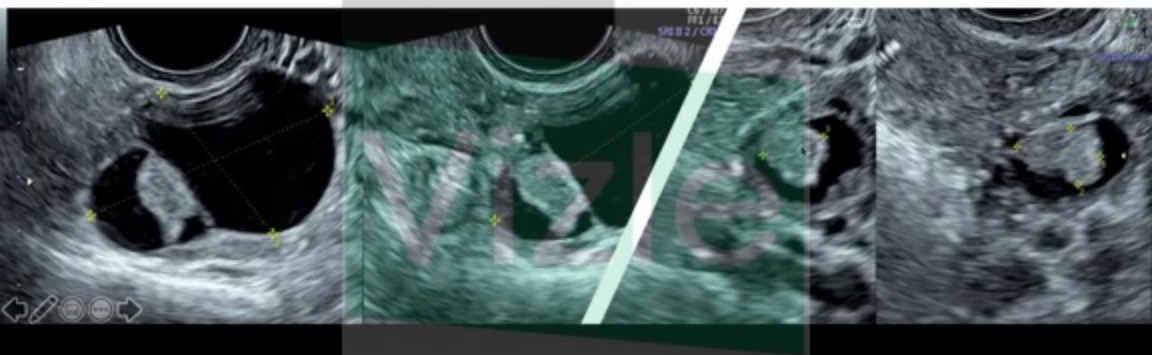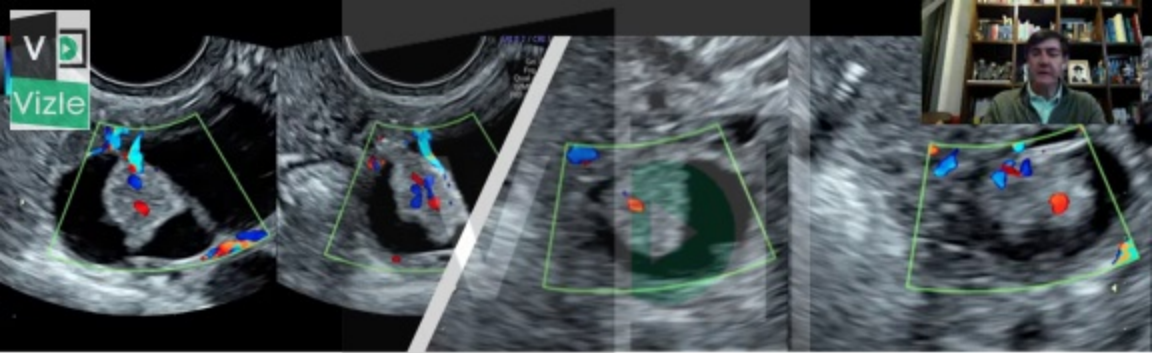


El tumor borderline seroso:

**Quiste unilocular grande
Unilocular sólido**

**Todos los unilocular sólidos
tienen papilas**

**Presenta las papilas con una zona
basal mayor y otras menores
escalonadas separadas**





Microscopía

El Borderline se distingue de los benignos

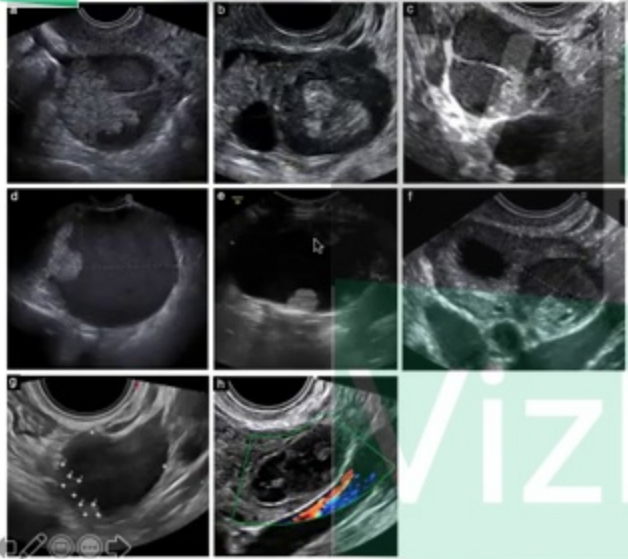


Por la proliferación celular y el variado grado de atipia nuclear



No tienen invasión estromal, excepto la variedad microinvasiva

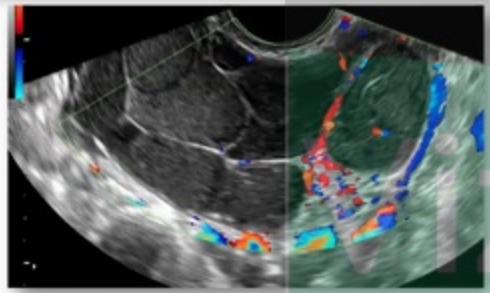
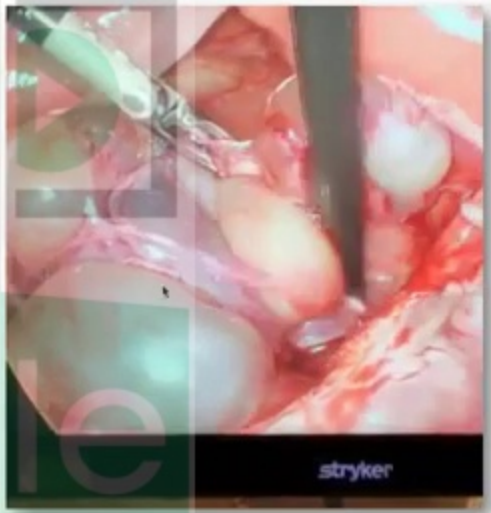
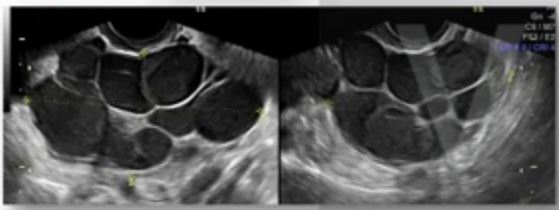
Los cistoadenomas pueden ser definidos como borderline cuando los focos de proliferación constituyen al menos el 10% del tumor, menor a eso se llaman cistoadenomas mucinosos con atipia focal



El tumor borderline mucinoso tipo endocervical:

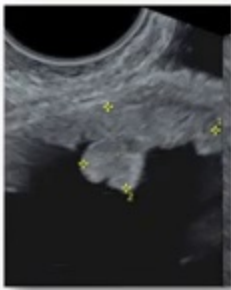
- Multilocular sólido
- Unilocular sólido
- Frecuentemente con papilas

Vizle

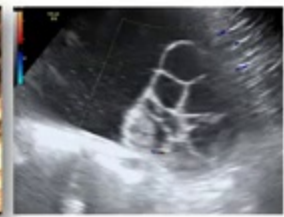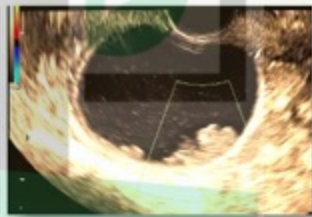





Patrón de reconocimiento



SBOTs



Vizle

This PDF is generated automatically by **Vizle**.
Slides created *only for a few minutes* of your Video.



For the full PDF, please **Login to Vizle**.

<https://vizle.offnote.co> (Login via Google, top-right)

Stay connected with us:

Join us on **Facebook, Discord, Quora, Telegram**.