

This PC, Icecream Ebook..., cairo scan lectures, MPC-HC x64, Recycle Bin, iTunes, cases brain 2015, Musculoske... MRI (Helms..., Control Panel, Mozilla Firefox, lecture schedua..., New Microsof..., Adobe Acrobat..., RadiAnt DICO..., my cases, New Microsof..., Adobe FormsCentral, VLC media player, CamRec0, Pediatric Neuroimag..., Camtasia 9, anatomy, Google Chrome, anatomy lectures, Internet Downlo..., third edition - Shortcut, Hotspot Shield, brain, kara para ask album - Sh...

Taskbar: Windows Start, File Explorer, VLC media player, CamRec0, Chrome, PDF, iTunes, Adobe Acrobat, PowerPoint, MPC-HC x64, Camtasia 9, System tray: Keyboard, Network, Volume, ENG, 8:38 AM 8/28/2018

Desktop icons: anatomy of the orbit, anatomy of the sinonas..., pathology of the orbit, degenerative spine dise...

Background: Large stylized 'V' and 'D' on a yellow background, and 'vizle' on a green background.

Background: Yellow and green geometric shapes.

This PDF is generated automatically by **Vizle**.
Slides created *only for a few minutes* of your Video.



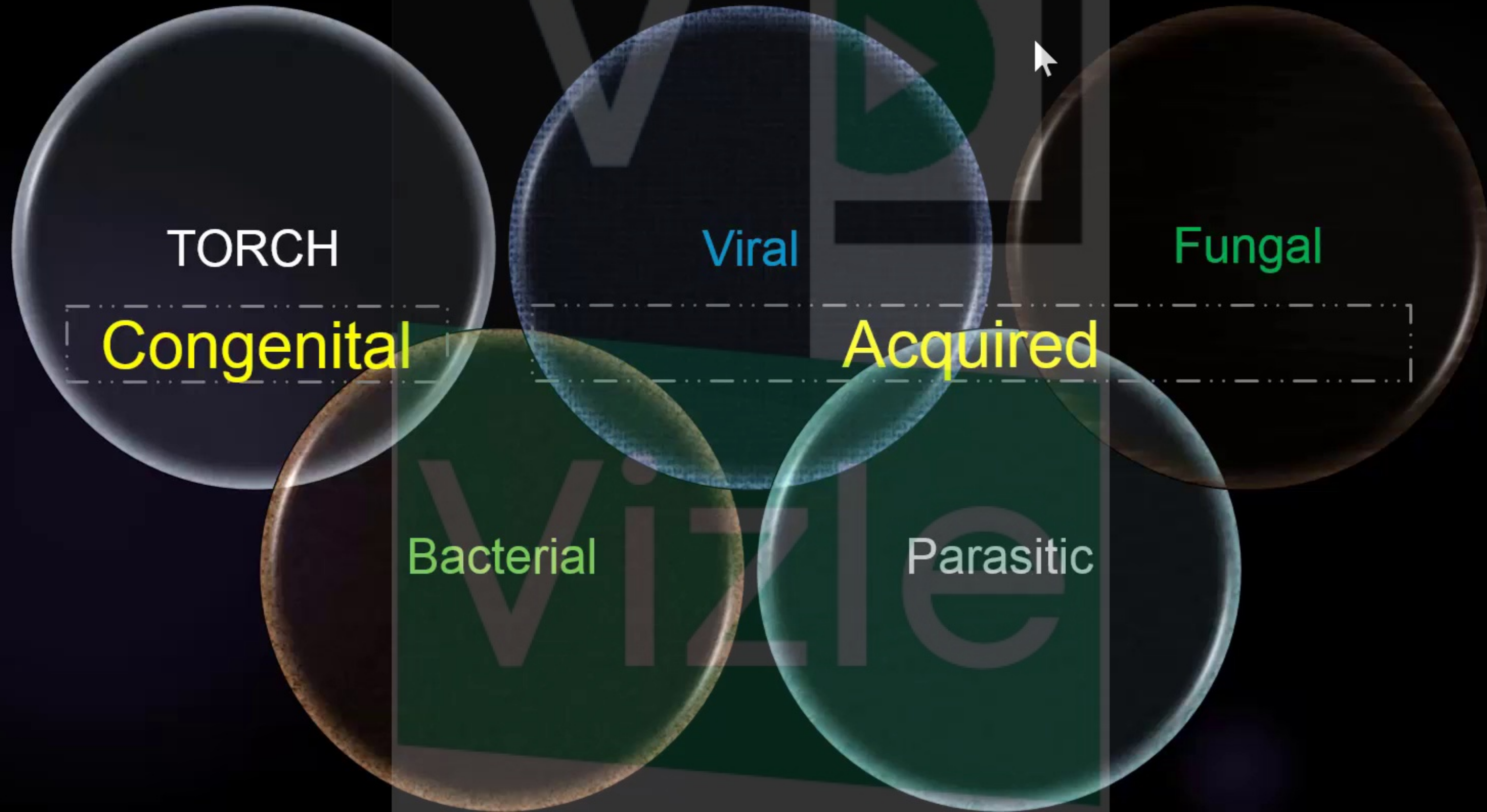
For the full PDF, please **Login to Vizle**.

<https://vizle.offnote.co> (Login via Google, top-right)

Stay connected with us:

Join us on **Facebook, Discord, Quora, Telegram**.

CNS infection



TORCH Infections

Toxoplasma gondii, **R**ubella, **C**ytomegalovirus (CMV) and **H**erpesviruses

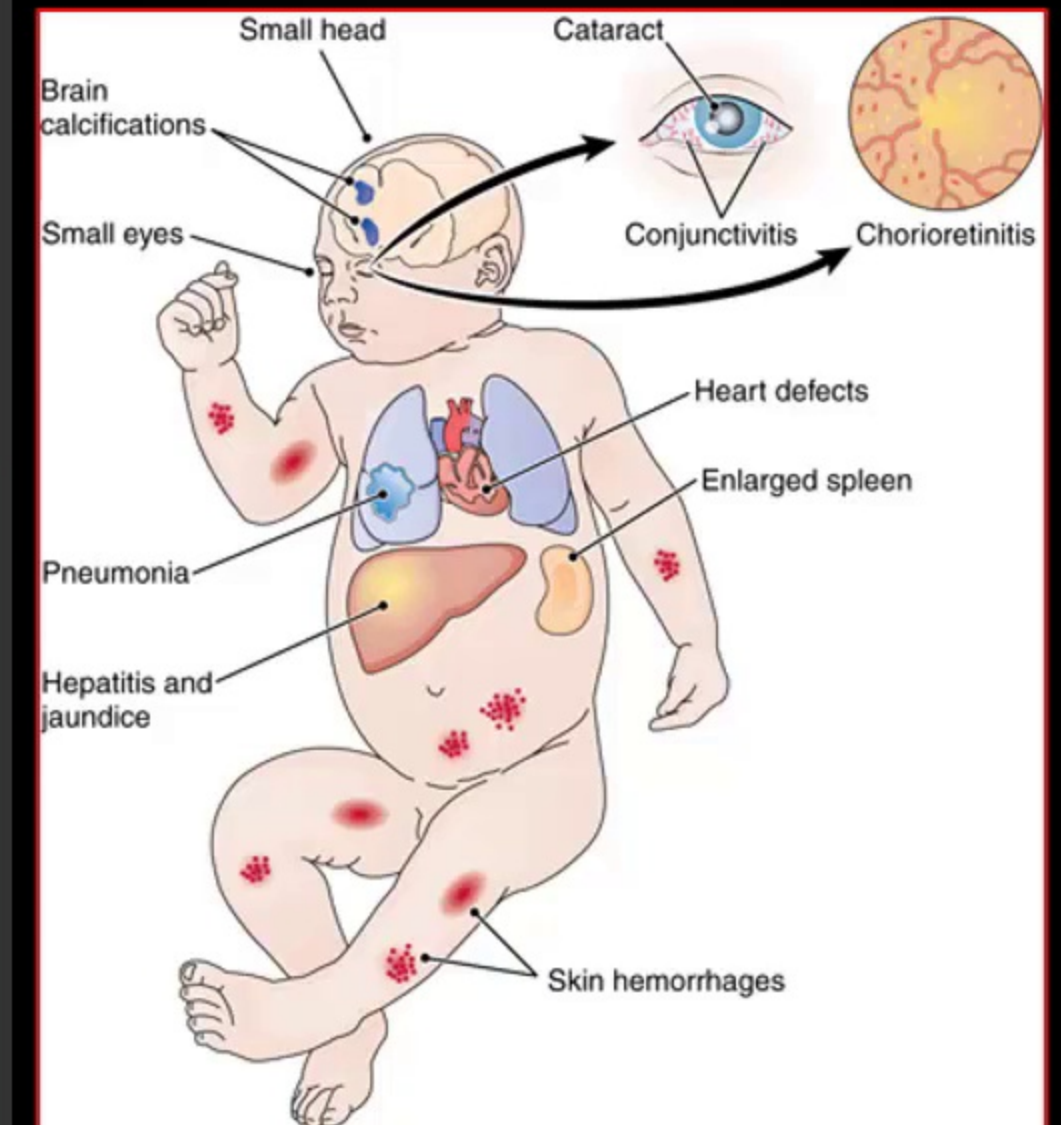
▪ Definitions

- Congenital infections caused by **transplacental transmission** of pathogens

- Toxoplasmosis (toxoplasmosis): *Toxoplasma gondii*
- Rubella: Rubella virus
- Cytomegalovirus (CMV): **Most common** TORCH infection
- Herpes: Herpes simplex virus 2 (HSV-2)
- Other: Human immunodeficiency virus (HIV), lymphocytic choriomeningitis (LCM), syphilis

▪ Most common signs /symptom

- Consider TORCH infection in newborn and infant with **microcephaly**, **ocular abnormalities**, and **intrauterine growth restriction**.

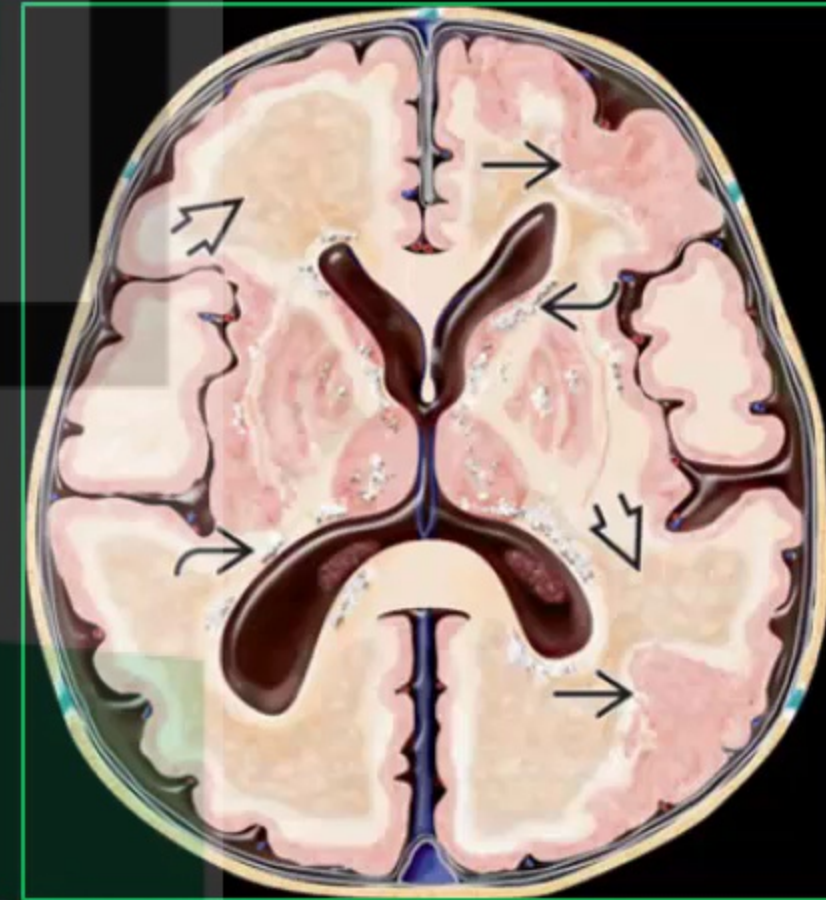
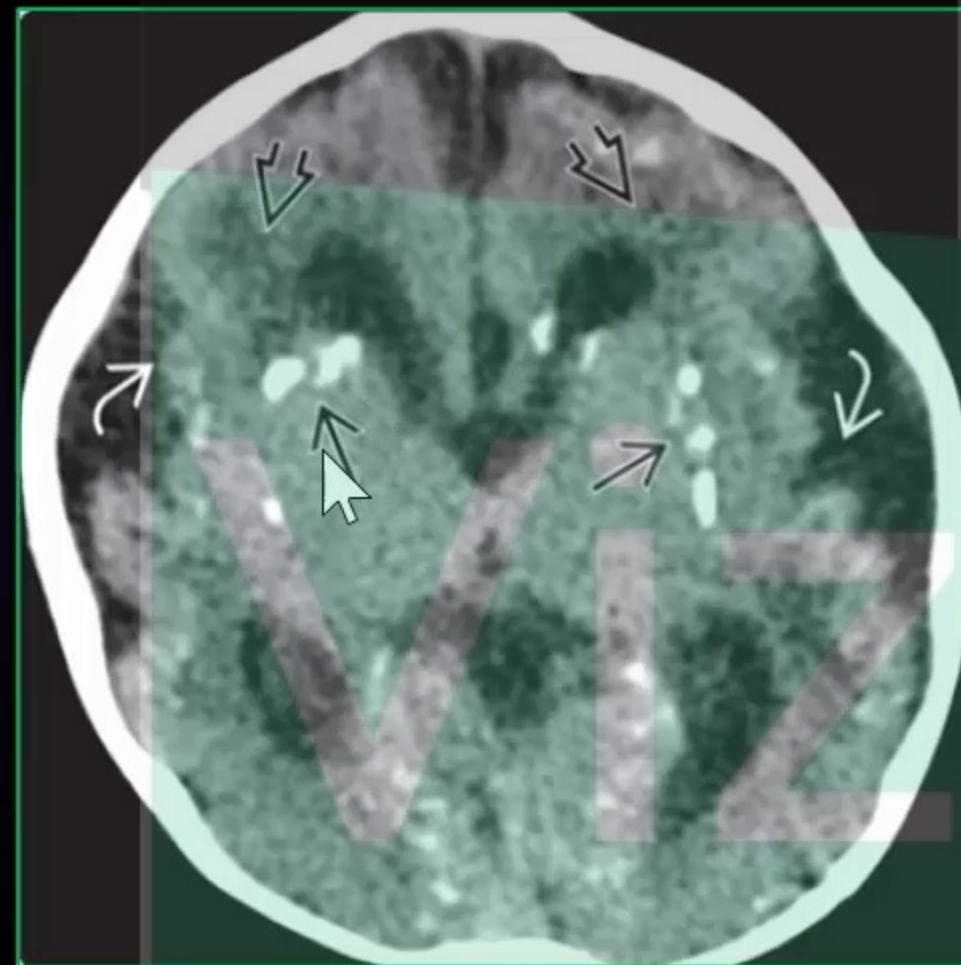


TORCH Infections

Toxoplasma gondii, **R**ubella, **C**ytomegalovirus (CMV) and **H**erpesviruses

- All cause parenchymal calcifications (Ca++)

Best
diagnostic clue

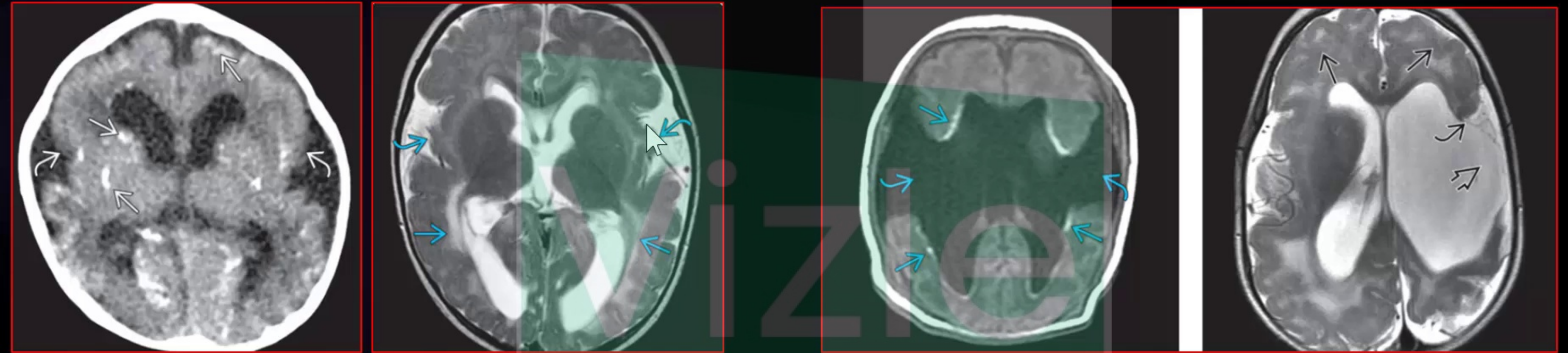


TORCH Infections

Toxoplasma gondii, **R**ubella, **C**ytomegalovirus (CMV) and **H**erpesviruses

- CMV causes **clefts**, **schizencephaly**, and migrational defects


CMV



CNS infection

Acquired
Bacterial ,viral

Immunocompromised
DM ,HIV, Post transplant...



- Bacterial
- Fungal
- Parasite

Immunocompetent



- Bacterial
- Viral
- Parasite

CNS infection



Immunocompetent

Bacterial

Acquired
Bacterial ,viral

Pyogenic (staph ,strep)


Meningitis
Empyema
Abscess
Ventriculitis

Fever

Direct
Hematogenous

Infants
Children
Adult

This PDF is generated automatically by **Vizle**.
Slides created *only for a few minutes* of your Video.



For the full PDF, please **Login to Vizle**.

<https://vizle.offnote.co> (Login via Google, top-right)

Stay connected with us:

Join us on **Facebook, Discord, Quora, Telegram**.