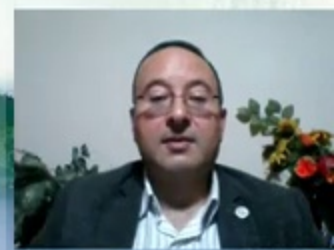



vizle





<https://vizle.offnote.co>

Contact us: vizle@offnote.co

This document was generated automatically by **Vizle**

Your **Personal Video Reader Assistant**

Learn from Videos **Faster** and **Smarter**

VIZLE **PRO / BIZ**

PDF, PPT ~~Watermarks~~

- Convert *entire* videos
- *Customize* to retain all essential content
- Include Spoken *Transcripts*
- Customer support

Visit <https://vizle.offnote.co/pricing> to learn more

VIZLE **FREE PLAN**

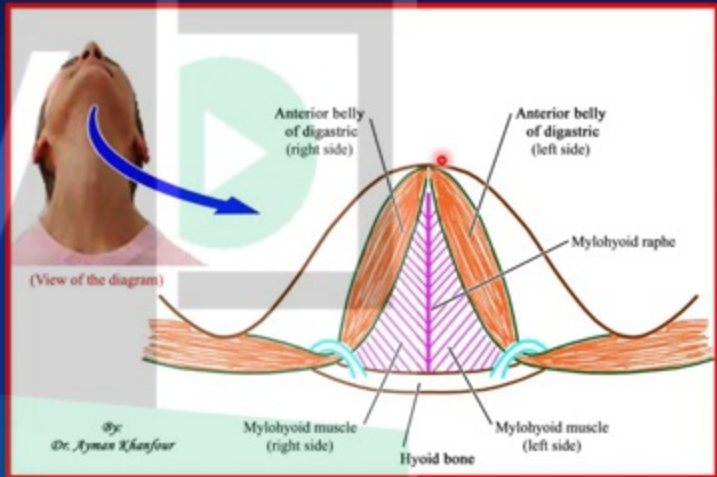
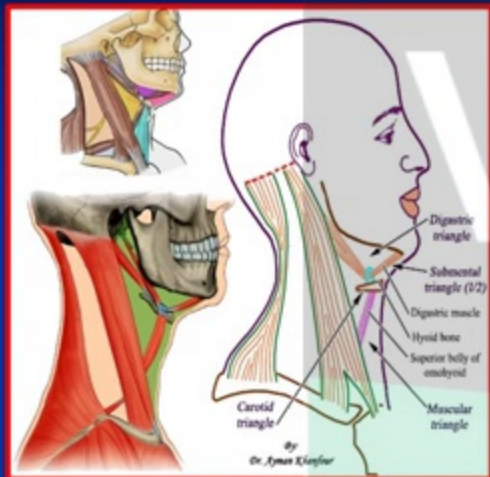
PDF only ~~Watermarks~~

- Convert videos *partially*
- Slides may be *skipped**
- Usage restrictions
- No Customer support

Visit <https://vizle.offnote.co> to try free

Login to Vizle to unlock more slides*

Boundaries



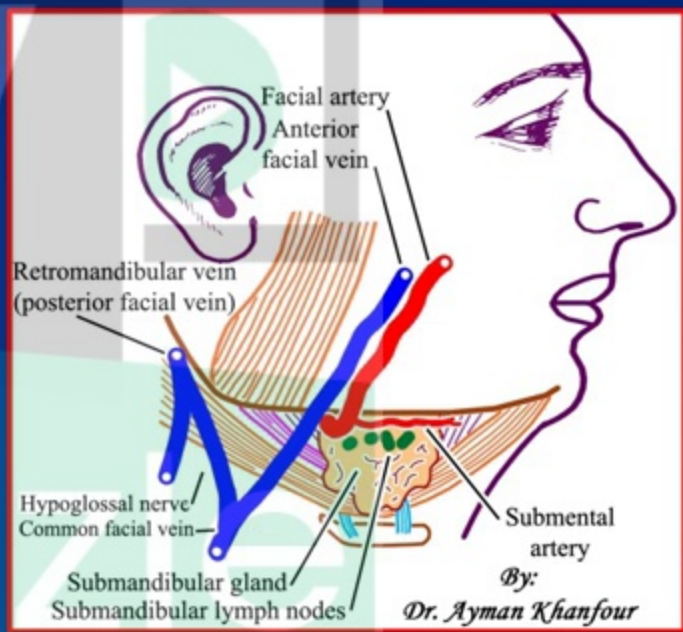
- ❑ Base: Hyoid bone
- ❑ On each side: Anterior belly of digastric muscle
- ❑ Apex: Symphysis menti



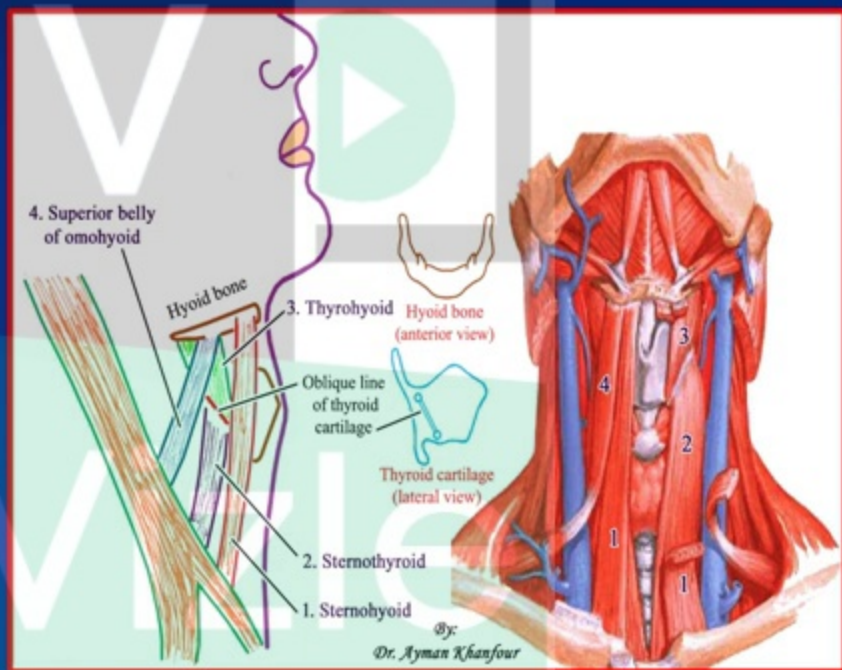
Contents

(2 submandibular + 3 vessels + 3 nerves + 1 ganglion + 1 sheath)

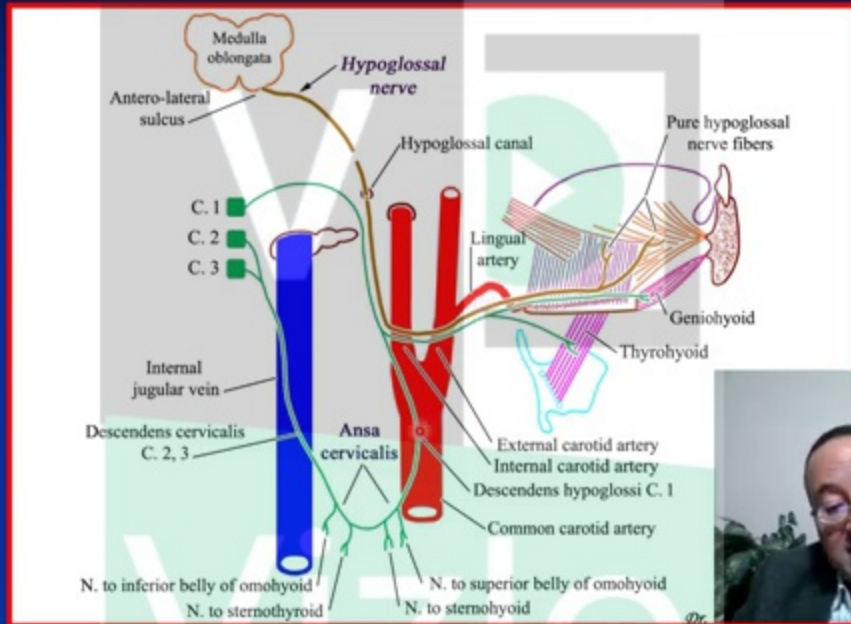
1. Submandibular salivary gland
(it occupies most of the triangle)
2. Submandibular lymph nodes.



Floor and Contents



Nerve supply:



- All the infrahyoid muscles are supplied by “ansa cervicalis” EXCEPT thyrohyoid which is supplied by the *nerve to thyrohyoid* (from the hypoglossal nerve through its C. 1 component).



<https://vizle.offnote.co>

Contact us: vizle@offnote.co

This document was generated automatically by **Vizle**

Your **Personal Video Reader Assistant**

Learn from Videos **Faster** and **Smarter**

VIZLE PRO / BIZ

PDF, PPT Watermarks

- Convert *entire* videos
- *Customize* to retain all essential content
- Include Spoken *Transcripts*
- Customer support

Visit <https://vizle.offnote.co/pricing> to learn more

VIZLE FREE PLAN

PDF only Watermarks

- Convert videos *partially*
- Slides may be *skipped**
- Usage restrictions
- No Customer support

Visit <https://vizle.offnote.co> to try free

Login to Vizle to unlock more slides*